

Case report

Open Access

Achilles tendon rupture following surgical management for tendinopathy: a case report

Michael R Carmont* and Nicola Maffulli

Address: Department of Trauma & Orthopaedic Surgery, University Hospital of North Staffordshire, Keele University School of Medicine, Stoke on Trent, ST4 6QG, UK

Email: Michael R Carmont* - mcarmont@hotmail.com; Nicola Maffulli - n.maffulli@orth.keele.ac.uk

* Corresponding author

Published: 27 February 2007

Received: 17 September 2006

BMC Musculoskeletal Disorders 2007, **8**:19 doi:10.1186/1471-2474-8-19

Accepted: 27 February 2007

This article is available from: <http://www.biomedcentral.com/1471-2474/8/19>

© 2007 Carmont and Maffulli; licensee BioMed Central Ltd.

This is an Open Access article distributed under the terms of the Creative Commons Attribution License (<http://creativecommons.org/licenses/by/2.0>), which permits unrestricted use, distribution, and reproduction in any medium, provided the original work is properly cited.

Abstract

Background: Achilles tendinopathy is understood to be a failed healing response. Operative management is utilised following the failure of non-operative methods.

Case Presentation: We present a case of Achilles tendon rupture, sustained whilst isometrically loading the Achilles tendon during an eccentric loading exercise programme. Conclusion: Bilateral surgical exploration and debridement had previously been performed after conservative management of bilateral Achilles tendinopathy had been unsuccessful.

Background

Achilles tendinopathy is understood to be a failed healing response process involving separation of collagen bundles, increase of hydrophilic extracellular matrix, haphazard neovascularisation, and absence of inflammatory cells [1,2]. Patients present with pain and thickening of the tendon [3]. Tendinopathy may lead to reduced tensile strength and a predisposition to rupture [4]. Management aims to alleviate symptoms and reduce the theoretical risk of rupture. Conservative methods include eccentric loading exercises and the avoidance of aetiological factors [5]. Operative management is utilised following the failure of non-operative methods [6,7].

We report the case of a patient who experienced an Achilles tendon rupture following surgical exploration of Achilles tendinopathy.

Case Presentation

A 44 year old retired Police Officer had a 4 year history of bilateral Achilles tendinopathy. The ailment had been

managed conservatively with eccentric loading exercises and the avoidance of aetiological factors [5], but his symptoms failed to settle. The patient underwent surgical exploration to both tendons using a medial approach. The paratendon was excised, and fish mouth fasciotomies of the crural fascia were performed proximally [8]. Small similarly sized nodules were present in both tendons. Longitudinal tenotomies were performed through the nodules within the tendons, and the tendinopathic areas were excised. The fat from Kager's triangle was also detached from the anterior aspect of the tendon [8]. Post-operatively, the patient was immobilised in a below knee synthetic cast, fully weight bearing as able. The casts were removed two weeks after surgery, and routine rehabilitation consisting of 3–4 episodes of eccentric loading exercises as limited by pain, was commenced [9]. At five weeks following the operation, whilst standing on his toes, he experienced a sharp pain to his left Achilles tendon, and he was subsequently unable to weight bear.

On examination the day after this episode, Simmond's [10] and Matles's [11] tests suggested an acute rupture of his Achilles tendon. The leg was placed in a below knee synthetic cast with the ankle in equinus, and the tendon was repaired percutaneously [12]. Complete rupture of the tendon was noted at operation. Histology revealed findings consistent with Achilles tendinopathy although some of these changes may be secondary to initial surgery (Figure 1). Post-operative recovery was uneventful, and the patient recovered his full function.

Conclusion

Tendon healing occurs in three overlapping phases [3]. The initial phase lasts 24 hours, and involves an intense inflammatory response with neutrophils, monocytes and macrophages. Vasoactive and chemotactic mediators stimulate vascular permeability, angiogenesis and teno-

cyte proliferation with type III collagen being produced. The second proliferative phase commences after a few days, with peak synthesis of type III collagen. After approximately six weeks, the remodelling phase commences, with decreased cellularity and decreased collagen and glycosaminoglycan synthesis. Consolidation occurs, and the repair tissue becomes more fibrous and the collagen fibres become aligned according to the direction of stress, and a greater proportion of type I collagen is synthesised. Eventually over the course of twelve months, during the maturation stage of healing, the fibrous repair matures into scar tissue [3].

Stretching is likely to increase collagen synthesis and improve fibre alignment leading to an increased tensile strength during healing. This should occur once the inflammatory phase of healing has settled [13]. Eccentric

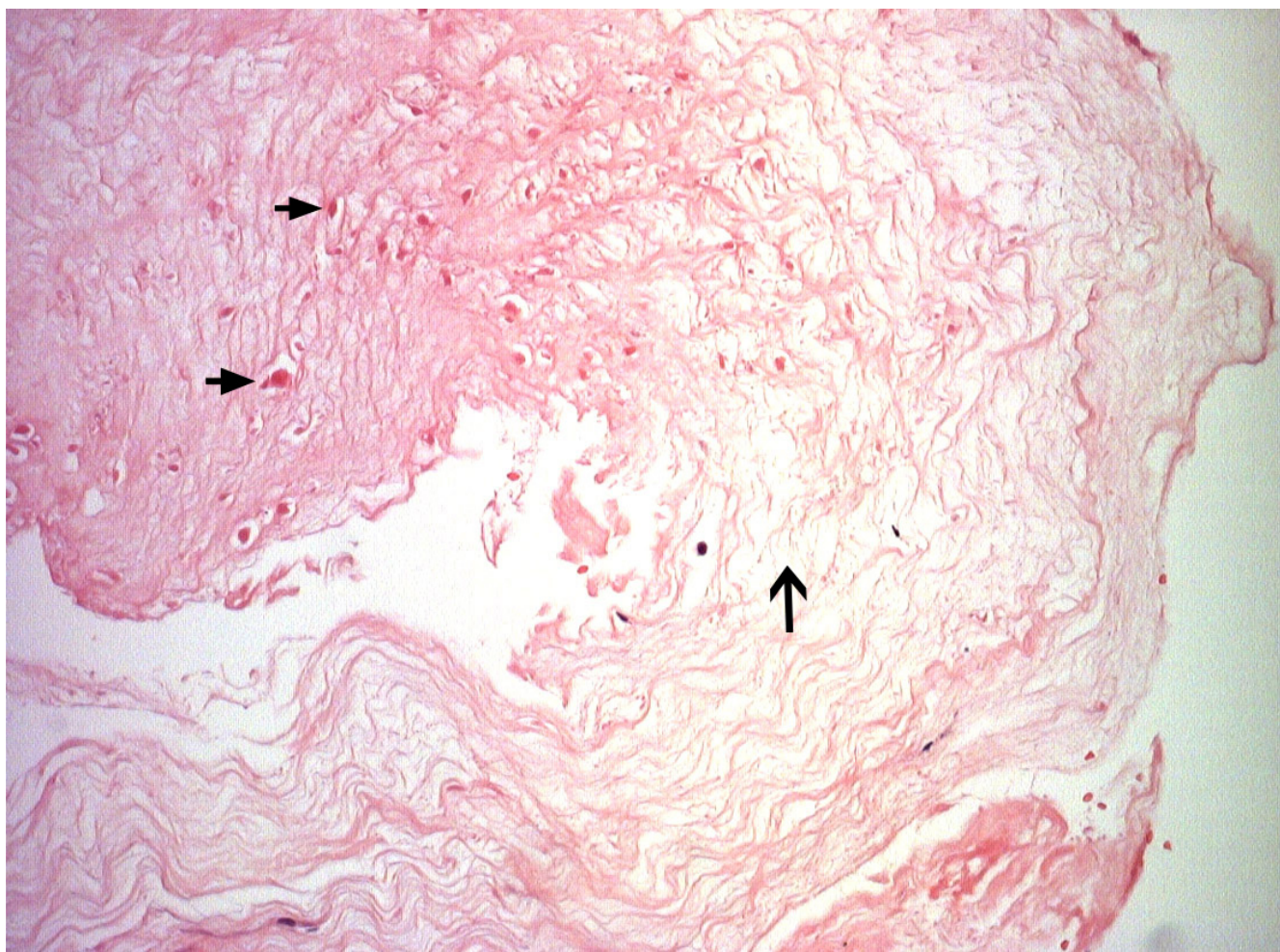


Figure 1

Histology of the tendinopathic tendon at repair (Transverse plane, $\times 20$ Magnification). Revealing scanty hypocellular degenerate tendon displaying separation of collagen fibrils (solid arrows) and disorganisation. Small pieces of fibrin (hollow arrow) were also present and there was no inflammation or neovascularisation.

loading has been shown to produce better outcomes than with concentric loading exercises [14,15]. These exercise programmes have been shown to reduce pain and improve function, although their effectiveness in the general population has recently been considered [16]. Ultrasound scanning shows reduced tendon thickness and intratendinous signal [17], which can normalise following successful management [18].

Eccentric loading exercises form the basis of non-operative management, and most patients will respond if recognised early. In patients with tendinopathy recalcitrant to non-operative measures, surgical exploration leads to good results [19-22]. We appreciate that there are several surgical methods, that it is not known which is the best way to remove degenerate tissue and that prolonged recovery following surgery may occur. Surgery removes adhesions and degenerate areas and other factors that influence local circulation [23].

No management is without complication, and these procedures carry a post-operative complication rate of up to 11% [24]. However, we believe that Achilles tendon rupture following surgical exploration for tendinopathy has not been previously reported [25]. At post-operative rehabilitation, the patient was attempting to stand on tip toes from a midstance position, thus performing an isometric loading exercise when his tendon ruptured. This was at five weeks following surgery at the end of the proliferative phase of tendon healing. Eccentric exercises are commonly performed in the rehabilitation programme following surgery for Achilles tendinopathy, they are considered safe, and we do not know why they resulted in a rupture in this particular patient. We appreciate that it may be difficult for a patient to recount the exact position and movement of the ankle at the time of rupture, our patient had already undertaken, all be it unsuccessfully, an eccentric exercise programme for his tendinopathies. Also, we cannot explain why only one tendon was affected, as both tendons were the same to visual inspection, underwent the same surgical procedure, and the same post-operative management regimen.

Competing interests

The author(s) declare that they have no competing interests.

Authors' contributions

MC wrote the case report including performing the literature review. NM is an experienced Trauma & Orthopaedic Surgeon with an interest in the Achilles tendon. NM provided guidance for the literature search, the writing of the paper and also proof read the paper. Both authors have read and approved the final manuscript.

Acknowledgements

We thank the Departments of Medical Illustration and Histopathology for their assistance with this case report. Written consent was obtained from the patient for publication of the study. No funding has been received for the study.

References

- Jozsa L, Kannus P: *Human tendon: anatomy and physiology and pathology* Human Kinetics, Champaign, USA; 1997.
- Maffulli N, Ewen SW: **Tenocytes from ruptured and tendinopathic Achilles tendons produce greater quantities of type I collagen than tenocytes from normal Achilles tendons: an in vitro model of human tendon healing.** *Am J Sports Med* 2000, **28(4)**:499-505.
- Sharma P, Maffulli N: **Tendon injury and tendinopathy: healing and repair.** *J Bone Joint Surg* 2005, **87-A(1)**:187-202.
- Tallon C, Maffulli N, Ewen SW: **Ruptured Achilles tendons are significantly more degenerated than tendinopathic tendons.** *Med Sci Sport Exerc* 2001, **33**:1983-90.
- Alfredson H: **Conservative management of Achilles tendinopathy: new ideas.** *Foot Ankle Clinics* 2005, **10(2)**:321-329.
- Sorosky B, Press J, Plastaras C, Rittenberg J: **Practical management of Achilles tendinopathy.** *Clin J Sport Med* 2004, **14(1)**:40-44.
- Vora AM, Myerson MS, Oliva F, Maffulli N: **Tendinopathy in the main body of the Achilles tendon.** *Foot Ankle Clinics* 2005, **10(2)**:293-308.
- Maffulli N: **Current concepts in the management of subcutaneous tears of the Achilles tendon.** *Bull Hosp Jt Dis* 1998, **57(3)**:152-158.
- Maffulli N, Testa V, Capasso G, Oliva F, Sullo A, Benazzo F, Regine R, King JB: **Surgery for chronic Achilles tendinopathy yields worse results in non-athletic patients.** *Clin J Sports Med* 2006, **16(2)**:123-128.
- Simmonds FA: **The diagnosis of the ruptured Achilles tendon.** *Practitioner* 1957, **179(1069)**:56-8.
- Matles AL: **Rupture of the tendo Achilles. Another diagnostic sign.** *Bull Hosp Joint Dis* 1975, **36(1)**:48-51.
- McClelland D, Maffulli N: **Percutaneous repair of the ruptured Achilles tendon.** *J R Coll Surg Edinb* 2002, **47(4)**:613-8.
- Houglum P: **Soft tissue healing and it's impact on rehabilitation.** *J Sports Rehab* 1992, **1**:19-39.
- Mafi N, Lorentzan R, Alfredson H: **Superior short term results with eccentric calf muscle training compared to concentric training in a randomised prospective multicentre study on patients with chronic Achilles tendinosis.** *Knee Surg Sports Traumatol Arthrosc* 2001, **9(1)**:42-47.
- Roos EM, Engstrom M, Lagerquist A, Soderberg B: **Clinical improvement after 6 weeks of eccentric exercise in patients with mid portion Achilles tendinopathy – a randomised trial with one year follow up.** *Scand J Med Sci Sport* 2004, **14(5)**:286-95.
- Sayana MK, Maffulli N: **Eccentric calf muscle training in non athletic patients with Achilles tendinopathy.** *J Sci Med Sport* in press. 2006 Jul 5
- Shalabi A, Kristofferson-Wiberg M, Svensson L, Aspelin P: **Eccentric training of gastrosoleus complex in chronic Achilles tendinopathy results in decreased tendon volume and intratendinous signal as evaluated by MRI.** *Am J Sports Med* 2004, **32(5)**:1286-96.
- Ohberg L, Lorentzon R, Alfredson H: **Eccentric training in patients with chronic Achilles tendinosis leads to normalised tissue and decreased thickness at follow up.** *Br J Sports Med* 2004, **38(1)**:8-11.
- Tallon C, Coleman BD, Khan KM, Maffulli N: **The outcome of surgery for chronic Achilles tendinopathy: a critical review.** *Am J Sports Med* 2001, **29(3)**:315-320.
- Paavola M, Kannus P, Orava S, Parsaren M, Jarvinen M: **Surgical treatment for chronic Achilles tendinopathy: a prospective 7 month follow up study.** *Br J Sports Med* 2002, **36(3)**:178-182.
- Chiara Vulpiani M, Guzzini M, Lenetti A: **The operative treatment of chronic Achilles tendinopathy.** *International Orthopaedics* 2003, **27(5)**:307-310.
- Saxena A, Cheung S: **Surgery for chronic Achilles tendinopathy: a review of 91 procedures over 10 years.** *J Am Podiatric Med Assoc* 2003, **93(4)**:283-291.

23. Kader D, Saxena A, Movin T, Maffulli N: **Achilles tendinopathy: some aspects of basic science and clinical management.** *Br J Sports Med* 2002, **36(4)**:29-244.
24. Paavola M, Orava S, Leppilahti J, Kannus P, Jarvinen M: **Chronic Achilles tendon overuse injury: complications after surgical treatment.** *Am J Sports Med* 2000, **28(1)**:77-82.
25. Young JS, Kumta SM, Maffulli N: **Achilles tendon rupture and tendinopathy: the management of complications.** *Foot Ankle Clinics* 2005, **10(2)**:371-382.

Pre-publication history

The pre-publication history for this paper can be accessed here:

<http://www.biomedcentral.com/1471-2474/8/19/prepub>

Publish with **BioMed Central** and every scientist can read your work free of charge

"BioMed Central will be the most significant development for disseminating the results of biomedical research in our lifetime."

Sir Paul Nurse, Cancer Research UK

Your research papers will be:

- available free of charge to the entire biomedical community
- peer reviewed and published immediately upon acceptance
- cited in PubMed and archived on PubMed Central
- yours — you keep the copyright

Submit your manuscript here:
http://www.biomedcentral.com/info/publishing_adv.asp

